JOURNAL OF TISSUE ENGINEERING AND REGENERATIVE MEDICINE
J Tissue Eng Regen Med (2013)
Published online in Wiley Online Library (wileyonlinelibrary.com) **DOI:** 10.1002/term.1760

REVIEW

Animal models for meniscus repair and regeneration‡

Daniela Deponti[1†], Alessia Di Giancamillo[1†], Celeste Scotti[1], Giuseppe M. Peretti[1,2] and Ivan Martin[3*]
[1]*IRCCS Istituto Ortopedico Galeazzi, Milan, Italy*
[2]*Department of Biomedical Sciences for Health, University of Milan, Italy*
[3]*Departments of Surgery and of Biomedicine, University Hospital Basel, Switzerland*

Abstract

The meniscus plays an important role in knee function and mechanics. Meniscal lesions, however, are common phenomena and this tissue is not able to achieve spontaneous successful repair, particularly in the inner avascular zone. Several animal models have been studied and proposed for testing different reparative approaches, as well as for studying regenerative methods aiming to restore the original shape and function of this structure. This review summarizes the gross anatomy, function, ultrastructure and biochemical composition of the knee meniscus in several animal models in comparison with the human meniscus. The relevance of the models is discussed from the point of view of basic research as well as of clinical translation for meniscal repair, substitution and regeneration. Finally, the advantages and disadvantages of each model for various research directions are critically discussed. Copyright © 2013 John Wiley & Sons, Ltd.

Received 10 August 2012; Revised 24 February 2013; Accepted 2 April 2013

Keywords **animal model; meniscus; tissue engineering; regenerative medicine; scaffold; biomaterials**

1. Introduction

Animal models are valuable tools for tissue pathophysiology studies and for testing new surgical solutions, devices and engineered implants for tissue regeneration. In particular, many studies belonging to the field of the tissue engineering aim to engineer a specific tissue and to validate its functionality in animal models, starting from preliminary evidences *in vitro*. Several studies have focused on the regeneration of the meniscus, since this tissue has a poor healing potential and easily degenerates over time. All the knowledge about meniscus pathophysiology has been obtained by studying the human meniscus but also that of several animal models. This allowed scientists to understand the mechanism leading to tear formation and tissue degeneration; moreover, these models allowed comparison of the efficacy of different devices for the repair of the meniscus achieved by a surgical approach. Finally, the different animal models allowed the validation of the proposed engineered tissues for the regeneration of this important structure *in vivo*. This review will compare and summarize the main animal models that have been used to study the repair and regeneration of the meniscus.

2. Gross anatomy

The knee joint meniscus is a fibrocartilaginous tissue that is in contact with both the femoral condyles and the tibial plateau. It is characterized by a 'semi-lunar' shape, having a bigger width in the posterior and anterior portions, respectively called the posterior and anterior horns, and a central area called the body. Both the medial and lateral menisci measure ca. 3.5 cm in length. Each meniscus has a thick and convex peripheral margin that is in contact with the inner capsule of the joint, while the opposite margin is represented by a thin free edge (Kohn and Moreno, 1995). The proximal and distal surfaces are characterized by different shapes, concave in the proximal one (the area of contact with the femoral condyles) and flat, respectively. The menisci can be divided into three main anatomical regions: (a) body; (b) cranial or anterior horn;

**Correspondence to: I. Martin, Institute for Surgical Research and Hospital Management, University-Hospital Basel, Hebelstrasse 20, 4031 Basel, Switzerland. E-mail: martini@usb.ch*
†These authors contributed equally to this study.
‡This article was published online on 27 May 2013. An error in the author affiliation was subsequently identified. This notice is included in the online and print versions to indicate that both have been corrected [2 August 2013].

(c) caudal or posterior horn. Knee joint menisci are found in all mammals and in other animals, but their shape and insertional anatomy vary considerably (Figure 1).

Recently, Proffen *et al.* (2012) have studied and compared the gross morphology of the human knee in six animal species (cow, sheep, goat, pig, dog and rabbit). An important finding of this study was that, in the human knee, the posterior horn of the lateral meniscus attaches anteriority to that of the medial meniscus, while in any of the other six animal species examined this feature was not seen. The same authors observed that the human medial meniscus width is significantly smaller than in the cow and larger than in the rabbit; moreover, the human medial meniscus is longer in all the studied species, with the exception of the cow. The anterior medial meniscus bony insertion is the most anterior structure found in the knee in all species. In fact, its insertion on the anterior edge of the tibial plateau is just above the tibial tuberosity in all species except the dog, whereas an intermeniscal ligament connects the most anterior sections of the medial meniscus to the lateral meniscus. The sheep and pig knees also present a small connection between the anterior medial and lateral meniscus insertions, but they do not overlap the distinct anterior insertion sites. The posterior horn of the medial meniscus attaches on the lateral edge of the posterolateral surface of the medial spine. The goat, dog and rabbit insertion site areas are smaller than those noted in the human, cow, sheep and pig knees. Regarding the lateral meniscus, Proffen *et al.* (2012) revealed that its width is larger in humans than in rabbits but smaller than in cows, and it is typically longer than the medial meniscus, except for the cow. Furthermore, the human lateral meniscus covers a smaller portion of the lateral tibial plateau when compared to the other animals' knees. Anteriorly, the human lateral meniscus is attached to the lateral aspect of the lateral spine of the intercondylar eminence. The cow, sheep and pig lateral menisci split the anterior cruciate ligament (ACL) bundles, while the goat and dog lateral menisci pass behind the ACL. All of them attach close to the medial tibial spine. The rabbit anterior lateral meniscus attachment is even more medial, adjacent to the anterior horn of the medial meniscus. Posteriorly, the meniscofemoral ligament connects the lateral meniscus to the lateral back wall of the medial femoral condyle, more inferiorly in humans than in the other animals. Human, sheep, goat, dog and rabbit lateral menisci have a meniscotibial coronary ligament, with those of human, goat and dog being less robust than rabbit. In the rabbit, the insertional ligaments are easy to differentiate from the tissue of the meniscal horn by a distinct change in tissue stiffness on palpation (Gao *et al.*, 1994).

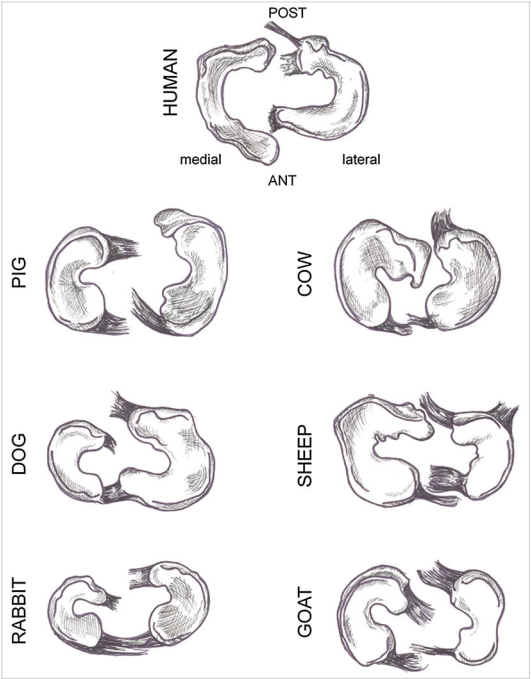

Figure 1. Different aspects of the menisci of seven species: human vs pig, cow, dog, sheep, rabbit and goat. The morphology of the menisci is shown with the medial meniscus on the left, the lateral meniscus on the right and the anterior horns facing down

The cow, sheep and goat knees do not present a full-length fibula or proximal tibiofibular joint. Instead, a fused fibular head is attached to the lateral side of the tibial plateau and serve as an attachment site for the lateral meniscus. Furthermore, all animal knees contain an intracapsular, extra-articular, lateral long digital extensor tendon (LDET) that originates just inferiorly to the lateral edge of the patellar groove. The LDET is not present in the human knee. The function of the LDET appears to be dorsiflexion of the forefoot, especially during knee flexion.

These differences in anatomical characteristics between different animals and human reflect certain major differences in limb use and joint biomechanics, such as the quadruped gait, which affects the range of motion in extension and therefore may limit the validity of some animal models.

3. Ultrastructure and biochemistry of meniscal muscle

Normal human meniscal tissue has been found to be composed of 72% water, 22% collagen, 0.8% glycosaminoglycans (GAGs) and 0.12% DNA (Herwig *et al.*, 1984). The water content of meniscal tissue was found to be higher in specimens taken from posterior areas than those from central or anterior areas, but tissue samples from surface and deeper layers have similar contents. On a dry weight basis, normal adult menisci contain 78% collagen, 8% non-collagenous protein and 1% hexosamine (Ingman *et al.*, 1974). The meniscal body consists predominantly of a dense framework of coarse type I collagen fibres with circumferential orientation. Radial fibres are found throughout the tissue but are less numerous. These latter may act as 'ties' holding the circumferential fibres together and opposing longitudinal stresses (Bullough *et al.*, 1970; Beaupre *et al.*, 1986; Ghosh and Taylor, 1987; Merkel, 1980). The collagens are heavily crosslinked by hydroxylpyridinium

DOI: 10.1002/term

aldehydes (Eyre and Wu, 1983). Type I collagen accounts for 90%, whereas types II, III and V collagens form the remaining meniscal tissue collagens (Eyre and Wu, 1983; McDevitt and Webber, 1990). The distribution of the different collagens shows significant regional variations: collagen I is predominant in the peripheral area, while collagen II is restricted to the inner zone that shows cartilage-like properties (Chevrier *et al.*, 2009) (Figure 2, Table 1). The amount of collagens and non-collagen proteins is lower at sites of meniscal tissue degeneration, which may account for the inferior mechanical quality of this tissue (Ingman *et al.*, 1974; Herwig *et al.*, 1984). Normal human meniscal proteoglycans contain 40% chondroitin 6-sulphate, 10–20% chondroitin 4-sulphate, 20–30% dermatan sulphate and 15% keratan sulphate (Herwig *et al.*, 1984). This ratio is maintained under tissue culture conditions by a corresponding GAGs production (Verbruggen *et al.*, 1996).

Fibrochondrocytes represent the cellular component of the meniscus; they secrete the fibrocartilaginous matrix, reside within lacunae and are round to oval in shape, depending on the location within the tissue (Hellio Le Graverand *et al.*, 2001) (see Table 1).

Many studies evaluating the biochemical and ultrastructural meniscal composition have revealed regional differences within the meniscus (Adams and Muir, 1981; Kambic and McDevitt, 2005). A pervasive finding is that the inner, or axial, portion of the meniscus has a composition closer to that of hyaline cartilage, as indicated by increased GAGs content (specifically aggrecan) and increased collagen type II content. This regional organization of the meniscal tissue composition has been evaluated in different animal models showing a strong similarity to the human model. Table 1 summarizes and compares the main meniscus components in all these models.

4. Blood supply

Blood vessels could be identified in the peripheral one-third of the menisci around week 22 of gestation in humans (Petersen and Tillmann, 1995). At birth, almost the entire meniscus is vascularized. In the second year of life, an avascular area develops along the central margins of the menisci. As a result, the insertional ligaments are vascularized but not the fibrocartilages (Petersen and Tillmann, 1998). Vascular supply to the menisci is provided by the lateral and medial geniculate arteries, which form a perimeniscal capillary plexus with radial branches directed towards the centre of the joint (Arnoczky and Warren, 1982). This is also observed in several animals used as *in vivo* models, such as cow, sheep, pig, dog and rabbit. In the adult, the degree of vascular penetration from the periphery was 10–30% of the width of the medial meniscus and 10–25% of that of the lateral meniscus. Chevrier *et al.* (2009) compared human, sheep and rabbit vascular supply to the meniscus and found that the patterns of vascularization they observed in human were similar to those in sheep (11–15% of meniscus length), while vascularization in rabbit menisci was distinctly lower and limited to the extreme periphery of the meniscal body (1% of meniscus length). This finding is consistent with a previous study (Bland and Ashhurst, 1996), which stated that few vessels were seen penetrating the rabbit menisci postnatally. Importantly, vascularization of adult pig menisci resembles that of adult humans (Peretti *et al.*, 2004).

5. Innervation

Innervation to the menisci provides proprioception and arises mainly from the posterior articular nerve, but part of the innervation of the medial meniscus is provided by branches of the medial articular nerve (Freeman and Wyke, 1967). There is general agreement that the nerve supply to the menisci is more extensive in the horns than in the body (Day *et al.*, 1985), similar to the vascularization pattern. O'Connor and McConnaughey (1978) demonstrated a rich neurovascular supply, including types I and II mechanoreceptors, in the meniscal horns in the cat, but could not detect any nerves in the body. In a later paper, O'Connor (1984) described a further two different type II receptors, and less commonly type III receptors, at the transitional zone between the posterior horn of the canine lateral meniscus. Similarly, Kennedy *et al.* (1982) found abundant axons, large nerve bundles, free nerve endings and specialized receptors, including complex end bulbs and Golgi-type (type III endings), in perimeniscal capsular

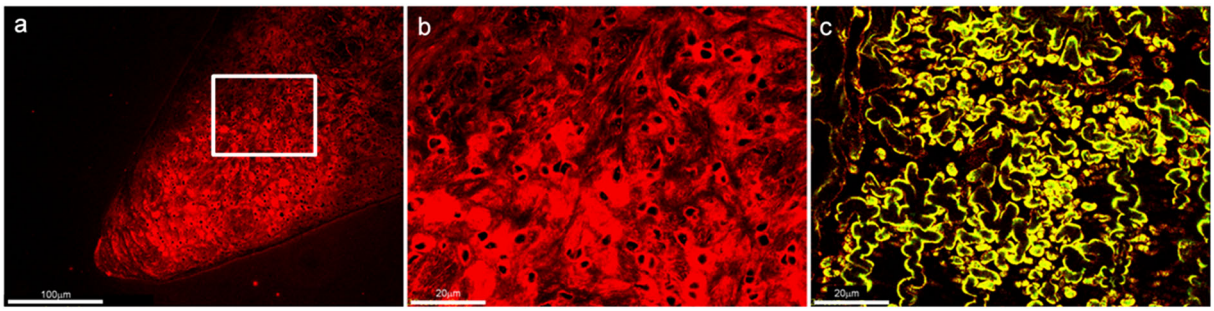

Figure 2. Adult pig, anterior horn: (a, b) in the inner zone, a strong immunopositivity to collagen type 2 is evident, due to the presence of a large amount of fibrochondrocytes (red); (c) in the outer zone, a co-localization of collagens type 1 and 2 is present in the circumferential fibres (yellow). The white square in (a) represents the area magnified in (b)

DOI: 10.1002/term

Table 1. Comparison of cell morphology, GAGs and collagen content among different animal models and human

	Human	Rabbit	Sheep	Calf	Pig	Dog
Cell morphology	Small ovoid in inner area, fibroblastic in external area (Furumatsu *et al*., 2011; Verdonk *et al*., 2005)	Ovoid or polygonal in deeper layers, fusiform at the surface (Ghadially *et al*., 1978) Chondrocyte-like in inner and middle zones, fibroblast-like in external zone (Moon *et al*., 1984; Bland and Ashhurst, 1996)	Round in deeper layers, fusiform at surface (Meller *et al*., 2009)	Round in inner zone; stellate in external zone (Son and Levenston, 2012)	Chondrocyte-like in inner and middle zones (Figure 2)	Round, chondrocyte-like in inner third, particularly in anterior and posterior horns; fibrocytes in the outer third (Somer and Somer, 1983)
GAGs content	Lower than rabbit and sheep models; present mainly in inner zone (Chevrier *et al*., 2009)	Present mainly in the inner zone (Chevrier *et al*., 2009). In anterior horn, present in both inner and middle zones (Killian *et al*., 2010)	Present mainly in inner zone (Chevrier *et al*., 2009)	Predominant in inner and middle zones (Collier and Ghosh, 1995)	High in inner zone, maily composed of chondroitin sulphate) (Nakano *et al*., 1997)	Aggrecan is more concentrated in inner zone, where it shows an organized network (Valiyaveettil *et al*., 2005)
Collagen I	Present throughout matrix except for inner tip, which is devoid of this collagen isoform (Chevrier *et al*., 2009)	Present throughout matrix except for inner tip, which is devoid of this collagen isoform (Chevrier *et al*., 2009)	Present throughout matrix except for inner tip, which is devoid of this collagen isoform (Chevrier *et al*., 2009)	Higher levels in external zone (Son and Levenston, 2012) but also present in inner zone (40%) (Cheung, 1987)	Higher levels in external zone, organized as circumferential fibres (Figure 2)	Present throughout matrix, from peripheral to inner area; forms circumferential fibres but not radial ones (Kambic and McDevitt, 2005)
Collagen II	Detected in the inner main body (Chevrier, Nelea *et al*., 2009)	Detected in inner main body (Chevrier *et al*., 2009)	Detected in inner main body (Chevrier *et al*., 2009). In young ovine restricted to inner zone (Smith *et al*., 2010)	Higher levels in inner zone, intermediate levels in middle zone and lower levels in outer zone (Son and Levenston, 2012). Inner zone characterized by 60% collagen II (Cheung, 1987)	High levels in inner and intermediate zones, organized as radial fibres (Figure 2)	Marked deposition in inner body, where it shows organized network in circumferential and radial fibres (Kambic and McDevitt, 2005)

DOI: 10.1002/term

tissue but not extending into the meniscal body. In contrast, Wilson *et al*. (1969) reported both myelinated and unmyelinated nerve fibres in the human medial meniscus that extended from a periarticular plexus onto the meniscus as far as its intermediate third of the body. These neural elements were not exclusively paravascular. Also, Zimny *et al*. (1988) showed nerves penetrating from the perimeniscal tissue into the peripheral and middle one-third of the meniscal fibrocartilage, especially near to the horns. A few years later, Biedert *et al*. (1992) described free nerve endings in the meniscofemoral ligaments of Humphry and Wrisberg, and the meniscal transverse ligament, the density of which was similar to that in the patellar tendon. The number of nerve endings was found to be decreased in older age (Assimakopoulos *et al*., 1992). These somewhat controversial reports regarding the distribution of different nerve endings in the meniscal body may be caused by the use of different classifications of anatomical regions. However, it is evident that encapsulated end organs with mechanoreceptor function predominate at the horns and attachment structures, and that free nerve endings are found throughout, except for the inner one-third of the meniscal body. Nerve filaments were further detected in the uncalcified and calcified fibrocartilages and the subchondral bone in both entheses of the rabbit medial meniscus (Gao *et al*., 1994). Therefore, it is broadly accepted that menisci have a sensory function, and especially their horns and insertional ligaments may provide important proprioceptive information related to joint position.

6. Meniscal injuries: animal models for meniscectomy

Meniscal lesions represent the most common intra-articular knee injury in the USA and are the most frequent cause of surgical procedures performed by orthopaedic surgeons (Morgan *et al*., 1991; Salata *et al*., 2010). The regional localization of a meniscal tear influences its healing capability, since the blood supply is restricted to the peripheral area of the meniscus: in fact, the perimeniscal capillary network allows for the spontaneous repair of the external region through different processes: (a) delivery of nutrients and oxygen; (b) infiltration of the wound site with cells involved in tissue repair (neutrophils, macrophages and lymphocytes, stem cells); (c) formation of blood clots and subsequent release of tissue remodelling mediators at the wound site (Bray *et al*., 2001). On the contrary, the meniscal tears located in the avascular inner area of the meniscus are not able to repair spontaneously, leading to degeneration of the meniscal tissue. The removal of the whole meniscus, as a consequence of injury and tissue degeneration, leads to the development of osteoarthritis (OA). Different meniscectomy animal models have been studied in order to evaluate the functions of the meniscus in the maintenance of cartilage stability and to determine the events involved in OA that are a consequence of the meniscus removal. These animal models will be described in order to highlight their contribution in defining the role of the meniscus in knee stability and biomechanical integrity and, therefore, in the preservation of knee health.

6.1. Sheep

Medial meniscectomy was performed in a sheep model in order to correlate the influence of physical exercise to OA progression: this study demonstrated that meniscectomized animals subjected to the exercise programme developed more severe cartilage lesions and osteophytes than their unexercised counterparts (Armstrong *et al*., 1993). Little *et al*. (1997) demonstrated that lateral meniscectomy results in histomorphological and immunohistochemical cartilage changes, similar to those described for early OA in humans. In particular, it was demonstrated that lateral meniscectomy induced an alteration in collagen organization of the articular cartilage, with a loss of proteoglycan content: these changes occurred within the middle and outer regions of the lateral tibial compartment, corresponding to areas that were previously protected by the lateral meniscus (Appleyard *et al*., 2003). Similar results were obtained by Oakley *et al*. (2004), demonstrating that total meniscectomy was able to induce significant changes in cartilage stiffness and thickness and that the patterns of temporal change varied in the different locations. Moreover, it was demonstrated that meniscectomy significantly changed joint alignment and surface interaction; in particular, the cartilage was damaged at the locations of minimum tibiofemoral distance, suggesting that increased contact stress is likely the primary driver of cartilage damage in this model (Beveridge *et al*., 2011). Among the changes affecting articular cartilage, the expression of proteoglycan-4 was found to be reduced by the absence of the lateral meniscus, particularly in the cells of the superficial zone (Young *et al*., 2006).

6.2. Dog

This animal model is characterized by a strong intrinsic response to tissue damage by deposition of fibrous tissue (Bendele, 2001). Different types of medial meniscectomy have been compared in order to assess the relationship between spontaneous meniscus repair and cartilage degeneration: two different mechanisms of meniscal repair were observed, depending on whether meniscal section were performed in vascular or avascular zones. It was also observed that the repaired meniscal tissue did not prevent articular cartilage degeneration: this was, however, more closely related to the size of the meniscal fragment preserved at meniscectomy (Berjon *et al*., 1990). Moreover, it was demonstrated that the lesions occurring in cartilage proved to be more severe at the tibial plateau compared to the femoral condyle, while for both joint surfaces the predominant location was the central zone (Berjon *et al*., 1991). In a study by LeRoux *et al*. (2000), total medial meniscectomy was performed in order to determine articular cartilage changes in terms of mechanical properties, quantitative collagen microstructure and GAG concentration:

DOI: 10.1002/term

the study demonstrated that the compressive and shear moduli of tibial cartilage were reduced in response to meniscectomy, as well as GAG concentration; the degeneration associated with meniscectomy produced either erosion of the most superficial layer of articular cartilage or, alternatively, a loss of the collagen fibrillar pattern characteristic of the normal superficial zone. Also the tensile moduli of the cartilage decreased significantly following meniscectomy (Elliott *et al*., 1999). Then, partial medial meniscectomy was compared to a longitudinal tear in the posterior horn of the medial meniscus, a region that is mostly involved in knee stability. Both injuries appeared to affect the integrity of the cartilage surface significantly less than a total meniscectomy (Wyland *et al*., 2002), demonstrating that the extension of cartilage degeneration is proportional to the removed meniscal tissue.

6.3. Rabbit

Partial meniscectomy was performed in New Zealand White rabbits by Bendele (2001) and resulted in articular lesions that were very close to those observed in human OA. However, medial meniscectomy led to milder degenerative changes, with respect to humans, as a consequence of the rabbit's tendency to load the lateral side of the knee: for this reason, this animal model has been used extensively in order to test chondroprotective agents (Bendele, 2001; Moskowitz *et al*., 1973). In contrast, partial lateral meniscectomy reproducibly induced focal degenerative changes involving approximately half of the articular surfaces of the knee (Colombo *et al*., 1983). Partial lateral meniscectomy was performed in rabbits in order to evaluate changes in the chondrocytes of articular cartilage at an early stage of OA. During the early stages of degeneration, when the extent of degeneration was mild even in the central-degenerative region, the synthesis of type II collagen was enhanced at the centre of degeneration. As the degeneration increased in severity, however, the synthesis of type II collagen increased in the peripheral regions (where degeneration was still relatively mild) and decreased in the central-degenerative region (where the degeneration had already become severe) (Hotta *et al*., 2005), demonstrating a specific synthetic response of chondrocytes to meniscectomy. Another study focused also on the changes in the bone after meniscus removal and demonstrated that total medial meniscectomy was correlated to a decrease of bone mineral density in the medial proximal tibia (Messner *et al*., 2000). A limit for this model is, however, represented by the great capacity of rabbits to regenerate the transected meniscus with fibrous tissue, as shown by opening the joints 6 weeks postsurgery (Bendele, 2001).

These animal models may mimic aspects of the pathogenesis and pathology of traumatic OA that occurs in humans. However, one important difference is that humans with a traumatic injury generally discontinue the use of the affected limb, while animals in the same situation generally do not. Consequently, disease progression is usually much more rapid in the animal models.

7. Meniscal repair

Upon the recognition that meniscectomy causes degeneration of the articular cartilage, the strategy of choice in handling meniscus lesions has to be a reparative approach. Meniscal repair techniques are in continuous evolution and consist of different approaches that have also been tested in some animal models.

7.1. Meniscal suture

Sutures are used to reconnect the torn tissue until bonding occurs. Several different suturing methods have been attempted, with the purpose of increasing the strength of the wound site. The first-generation repairs involve an open procedure: the repair is performed with vertically orientated, absorbable 4-0 sutures, incorporating the entire height of the meniscal rim and the capsular bed in an anatomical fashion. The ability to achieve a strong fixation is the main advantage of this technique, which is suitable for lesions within 3 mm from the peripheral rim. The main disadvantage is the risk of neural damage to the saphenous nerve or its branches. The second-generation repairs are based on arthroscopically assisted 'inside-out' or 'outside-in' technique; the goal is to reduce the morbidity associated with the posterior approach and to be able to repair meniscal lesions located in the red–white zone. In the 'inside-out' approach, absorbable or non-absorbable 2-0 or 0 sutures are passed from inside to outside, using long flexible needles. The posterior neurovascular structures are protected with a large retractor, but the risk of neurovascular complications still remains. In the 'outside-in' approach, introduced by Warren (1985), a cannulated 18-gauge spinal needle is passed across the tear from the outside in; once the sharp tip of the needle is in view, the suture (monofilament absorbable 0-gauge PDS) is passed through the lumen of the needle and pulled through the arthroscopic ipsilateral portal. An interference knot is tied in the end of the suture and the suture is pulled back. The process is repeated and the free ends are tied two by two over the capsule through an accessory skin incision until the tear is stabilized. Specific implants have been designed to replace the use of sutures and to allow 'all-inside' meniscal repairs without the need for accessory skin incisions. Staples, tacks, anchors, screws, etc. have been proposed; most of the devices are bioabsorbable and composed of rigid poly-L-lactic acid (PLLA); the disadvantages are the lower strength of the arrows compared to vertical sutures (Tengrootenhuysen *et al*., 2011) and the risk of loose bodies (Menche *et al*., 1999; Oliverson and Lintner, 2000), synovitis (Song *et al*., 2001), cysts (Hechtman and Uribe, 1999) and cartilage abrasion (Anderson *et al*., 2000; Otte *et al*., 2002) due to the head of the device at the surface of the meniscus. The newest devices are self-adjusting suture devices, combining the advantages of 'all-inside' meniscal repair (no accessory incision, lower neural complication rate) with those of

DOI: 10.1002/term

suture (better strength). These implants share the potential ability to deform and move with the meniscus during weight bearing and carry a lower risk of chondral abrasion. Many 'all-inside', suture-based devices are currently available, including the Meniscal Cinch (Arthrex, Naples, FL, USA), FasT-Fix (Smith & Nephew, Andover, MA, USA), Ultra FasT-Fix (Smith & Nephew), RapidLoc (Mitek, Westwood, MA, USA), MaxFire (Biomet, Warsaw, IN, USA) and the CrossFix System (Cayenne Medical, Scottsdale, AR, USA).

In order to highlight the advantages and disadvantages of all these techniques, they have been tested in several animal models for the repair of experimentally-induced meniscal tears. These studies focused mainly on the mechanical properties of the repaired menisci, comparing the new devices to the standard suturing approaches.

The *bovine* model has been widely used for the study of meniscus repair with a suturing approach. Several *ex vivo* studies have been done on isolated menisci in order to easily perform the biomechanical tests that are required to compare the standard vertical and horizontal sutures to the different 'all-inside' techniques. Rankin *et al*. (2002) performed 2 cm longitudinal tears in bovine medial menisci that were repaired with a vertical loop suture, a horizontal loop suture, a T-Fix and Biofix arrow device; they demonstrated that a vertical loop suture had superior biomechanical properties and that the 'all-inside' devices had inferior properties with respect to both the vertical and horizontal sutures. Other authors applied a wider panel of 'all-inside' devices for the repair of the bovine meniscus: T-Fix, Mitek, Clearfix screw, Clearfix dart, Biostinger, S-D-Sorb and Arthex dart were found to have inferior failure strength with respect to standard vertical and horizontal sutures in repairing the bovine meniscus. However, the T-Fix showed higher performances with respect to the other devices and this result was explained by its ability to hold as many fibres as horizontal techniques (Asik and Sener, 2002). Zantop *et al.* (2005) demonstrated that, on lateral bovine menisci, the Fast T-Fix displacement, the pull-out strength and the stiffness were comparable to those of vertical suture techniques, whereas the biomechanical characteristics of the RapidLoc device were comparable to those of the horizontal suture. Moreover, the 'all-inside' devices showed an inferior stiffness with respect to standard sutures when a shear load scenario, instead of a tensile one, was applied to the medial bovine meniscus in order to mimic the shear load that occurs with flexion and extension movements of the knee (Brucker *et al*., 2010).

The different suturing approaches have also been compared in the *pig ex vivo* model. Consistent with the bovine model, the vertical sutures were found to have superior biomechanical properties than those associated with rigid and flexible anchor techniques; the vertical suture techniques provide the most rigid fixation that is essential for meniscal tissue healing (Chang *et al*., 2009). Two standard vertical 'inside-out' techniques (Ultrabraid and Fibrewire) were compared to two 'all-inside' techniques (Ultra FastT-Fix and Meniscal Cinch), demonstrating that Fibrewire could lead to the strongest repair in load-to-failure testing (Rosso *et al*., 2011). Another study in pigs examined the biomechanical effect of a posterior horn radial tear of the medial meniscus and the effect of pullout sutures for its repair: this approach was found not to be sufficient to decrease the medial tibiofemoral contact pressure at 0° and 15° of flexion, which is the position of the knee joint during normal gait in humans (Seo *et al*., 2009).

The *goat* has also been used in some *in vivo* models of meniscal repair (Miller *et al*., 1995, 2004; Ritchie *et al*., 1998). In these studies, the majority (85–93%) of surgically created tears in the goat model healed with a modified 'inside-out' technique. Furthermore, some meniscal repair devices caused chondral injury, and no device was found to be superior to the 'inside-out' suture repair (Miller *et al*., 1995, 2004; Hospodar *et al*., 2009).

The ideal tissue for this kind of study should be the one from fresh, young human cadaver donors. However, the availability of young human menisci is very limited and, for this reason, different animal models have been used in order to mimic as much as possible the reparative potential and the mechanical behaviour of human menisci. However, all of them show some limitations. The goat meniscus has been considered too small to provide a realistic model for arrow insertion (Asik and Sener, 2002), while structural, morphometric and biomechanical properties of the bovine meniscus approximately resemble the properties of the human meniscus (Proctor *et al*., 1989); in particular, 4 month-old calf menisci are considered more similar to human menisci (Asik and Sener, 2002). The porcine model seems to better represent the human meniscus, in particular in its size, shape and structure (Joshi *et al*., 1995), and is considered comparable to the young adult human meniscus (Barber and Herbert, 2000). However, some limitations have also been found in this model: the porcine menisci have higher mechanical properties than adult human menisci, displaying minimal deformation and equilibrium displacement in response to the visco-elastic creep response compared to bovine and human menisci (Proctor *et al*., 1989; Sweigart *et al*., 2004). For these reasons, the clinical relevance of these data has to be carefully considered.

7.2. Cell therapy

Human menisci are composed of different cell populations that are able to respond differently to the stimuli belonging to the matrix (Verdonk *et al*., 2005; Son and Levenston, 2012). According to the complex nature of the meniscal tissue, two cell populations have mainly been used in studies on meniscal healing: mesenchymal stem/stromal cells (MSCs) and chondrocytes.

An interesting approach is represented by the intra-articular injection of progenitor cells that can participate in and enhance tissue regeneration. A first report of this strategy was performed by Murphy *et al*. (2003) by injecting bone marrow-derived MSCs in suspension with sodium hyaluronan in an OA *goat* model, demonstrating

DOI: 10.1002/term

a successful cell survival and engraftment in the regenerated medial meniscus. In more recent studies, Horie *et al.* (2009, 2012) investigated the potential for meniscus regeneration of intra-articularly injected synovial membrane-derived MSCs in a *rat* massive meniscal defect model, showing active participation of the injected MSCs in the regeneration process, adhering to the injured sites and synthesizing new tissue.

In the *dog* model, autologous bone marrow-derived MSCs (BMSCs) were injected into meniscal wounds, allowing for a complete healing with a marked vasculogenesis (Abdel-Hamid *et al.*, 2005).

These studies suggest that cell therapy can ameliorate the local response to meniscal injury by stimulating tissue repair. However, this approach is characterized by the risk of non-specific engrafting of the cells and by the absence of a carrier that can mediate preliminary biomechanical functions in the lesion site. For these reasons, most studies have been done by associating different cell populations with scaffolds, in order to promote a regeneration of the meniscal tissue instead of stimulating spontaneous healing.

Chondrocytes have been considered a suitable population for the repair of meniscal lesions: the rationale is that these cells are able to produce a matrix that resembles that of the meniscus. These studies have been performed in the *pig* model, as it is characterized by the absence of spontaneous healing and it is very similar to the human (Peretti *et al.*, 2004). In a first study, chondrocytes were combined with devitalized meniscal chips as a carrier and then used to repair a longitudinal tear in the avascular region of the swine meniscus, demonstrating that these cells are able to produce a bonding tissue that resembles the cartilaginous and fibrocartilaginous matrix (Peretti *et al.*, 2004); moreover, the bonding between pig meniscal slices was improved by the use of fibrin glue as embedding material after ectopic implantation (Scotti *et al.*, 2009). In the same animal model, allogeneic and autologous chondrocytes, isolated from auricular and articular cartilage, were seeded into vicryl-mesh scaffolds and the cellular composites were implanted in bucket-handle lesions in the avascular area of the swine meniscus: in all experimental samples, some degree of new tissue formation was found and the newly formed tissue in all groups was uniform, having a characteristic fibrous tissue-like appearance. No data were produced for the determination of a specific matrix deposition into the engineered composites; however, the obtained results demonstrated that allogeneic cell populations can be used in combination with biodegradable scaffolds to repair tears in the meniscus (Weinand *et al.*, 2006).

7.3. Growth factors

Growth factors act on target cells by adhering to a specific receptor which triggers, by a system of signals or messengers, the activation of nuclear genes that determine cell proliferation, differentiation and death. The two areas of the meniscus, the vascular and the avascular areas, behave differently in terms of repair and their cells express different factors (Esparza *et al.*, 2012). In meniscus repair, the growth factors released by the cells at the site of injury, together with the inflammatory infiltration of the scar tissue, stimulate the meniscal cells to proliferation, migration, differentiation and matrix synthesis.

Local delivery of growth factors may stimulate native tissue repair or create a favourable environment for the rapid integration and maturation of engineered replacement materials. Direct application of recombinant human proteins is limited by their short biological life and the need for repeated high doses of the growth factor. For this reason, one extremely important aspect of treatment with growth factors is their insertion into suitable carriers, capable of controlled release, which can transport them into the tissue. Porous, biodegradable biomaterials are recommended, as they can maintain the concentration of growth factors in the place where they are inserted (Segawa *et al.*, 2009).

In the *sheep* model, some meniscal plugs were inserted *in vitro* into a lesion in the avascular area of the meniscus and then treated with TGFβ1 and IGF-1, demonstrating that a combination of these factors can aid in the repair of the avascular meniscal injuries by promoting the attachment of tissue and the proliferation of meniscal cells (Izal *et al.*, 2008). In this animal model, some growth factors were also tested *in vivo* in order to investigate their direct effect on spontaneous healing. In the case of VEGF-coated sutures, the treatment was found to be not sufficient to improve the rate of healing of the avascular region of the meniscus, despite the well-known angiogenetic potential of this growth factor (Kopf *et al.*, 2010). In the *cow* model, TGFβ3 and bFGF were found to positively modulate meniscus repair *in vitro* (Ionescu *et al.*, 2012) and TGFβ1 was found to be a potent stimulator of both protein and proteoglycan accumulation in meniscal explant cultures (Imler *et al.*, 2004). In the *rabbit* model, FGF-2 was used to treat a horizontal meniscal tear in combination with gelatin–hydrogel as a carrier: this treatment significantly stimulated proliferation and inhibited the death of meniscal cells, thereby increasing meniscal cell density and enhancing meniscal repair (Narita *et al.*, 2012). In a similar way, platelet-rich-plasma (PRP) associated with gelatin–hydrogel was able to enhance the spontaneous healing of the inner avascular area of the rabbit meniscus (Ishida *et al.*, 2007). Hyaluronan was also tested in this animal model in both the inner and peripheral regions of the meniscus: this factor was able to promote the repair of the external area by enhancing collagen remodelling, although the inner region did not achieve successful repair (Sonoda *et al.*, 2000).

The different animal models confirmed the important role of growth factors in regulating cell proliferation and synthetic activity during meniscus healing; however, all studies highlighted the limits of these factors in their *in vivo* applications. For this reason, they are mainly used in combination with cells and scaffolds in order to support their delivery and, at the same time, to enhance the regeneration potential of the engineered meniscal tissues.

DOI: 10.1002/term

8. Meniscal replacement and regeneration

The evidence that meniscus repair leads to the formation of a tissue with inferior properties (Newman *et al*., 1989) paved the way for the development of strategies for the partial or total substitution of the damaged meniscus with an engineered tissue or an allograft (Figure 3). Meniscal replacement strategies aim to regenerate a functional tissue that can mediate the mechanical functions required in the knee joint, avoiding the development of osteoarthritis. Studies on meniscus regeneration are summarized in Table 2.

8.1. Meniscus allograft

Meniscal allograft has the appealing feature that it may incorporate all of the necessary components of the native meniscus. To succeed, however, it must first bond to the remaining structure to facilitate revascularization and then repopulate with cells that will maintain the appropriate extracellular matrix (Stone *et al*., 1995). Meniscal allograft decelerates the progression of chondral damage in meniscectomized knees (McNickle *et al*., 2009) and this protective effect has been tested in various animal models.

In the *sheep* model, allogeneic frozen menisci were implanted in the knee joints and showed a chondroprotective effect in comparison to meniscectomy; the graft was repopulated by the host with cells derived from the synovium, particularly at the capsular and femoral surfaces, but the decrease in proteoglycan content persisted over time, suggesting an incomplete cell migration into the meniscal allograft (McNickle *et al*., 2009). In another study, fresh allogeneic menisci were implanted but, although this model demonstrated significant improvement compared to meniscectomy, progressive cartilage degeneration still occurred (Kelly *et al*., 2006). Similar results were obtained by Mora *et al*. (2003) using frozen meniscal allografts. In the *goat* model, studies were done in order to evaluate the difference between cryopreserved and deep-frozen meniscal tissue: no significant differences were observed and, although cryopreservation makes it possible to maintain a partial cell viability in the tissue, this approach does not seem to improve the morphological and biochemical characteristics of the graft (Fabbriciani *et al*., 1997). The allograft repopulation was also confirmed in another study in the goat model: Jackson and Simon (1993) found no donor DNA within the meniscal allograft at 4 weeks after transplantation, whereas the host DNA content approached or exceeded the amount present in the contralateral meniscus.

Several studies of meniscal allograft transplantation have been done in the *dog* model. Mikic *et al*. (1993) implanted fresh menisci in the dog knee and showed a repopulation of the allograft 8 and 12 months after implantation that, however, was lower than in the control tissue. Arnoczky *et al*. (1990) transplanted cryopreserved menisci in dogs and found a normal gross appearance of the grafts with a normal cell population and proteoglycan component 6 months after surgery, and revascularization with small vessels originating from capsular and synovial tissue. In another study using dogs, Arnoczky *et al*. (1992) studied cellular repopulation of deep-frozen meniscal autografts after reimplantation. Autoradiography showed that the freezing process effectively killed all cells in the meniscus but, 6 months after reimplantation, the menisci were repopulated with host cells from the synovium. A previous study from Arnoczky *et al*. (1988) demonstrated that the mechanical properties of transplanted cryopreserved menisci, such as tensile strength and elastic modulus, were

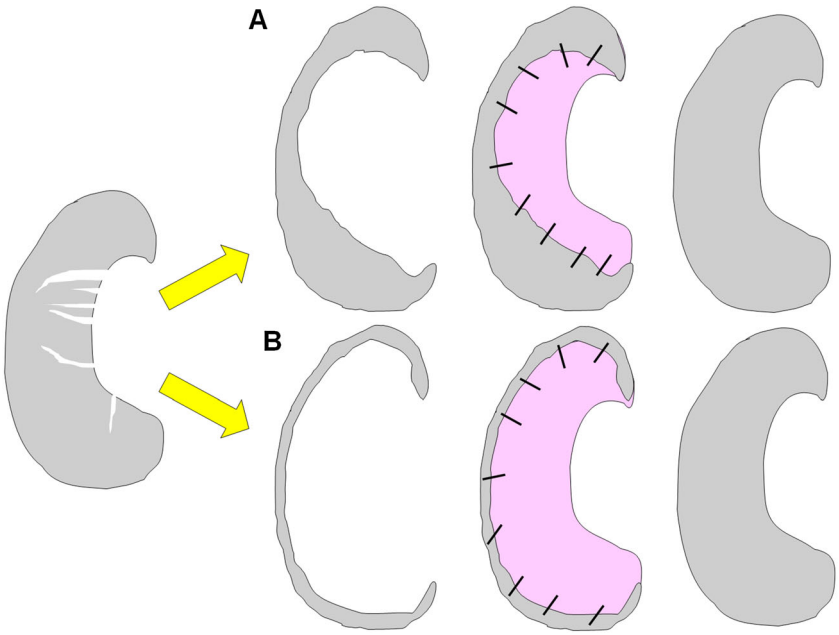

Figure 3. Schematic picture of partial (A) and total (B) meniscus regeneration

DOI: 10.1002/term

Table 2. Animal models for meniscus regeneration

Animal model	Scaffold type	Cell type	*In vivo* time	Outcome	Reference
Sheep	Polyurethane	No cells	6 and 12 months	Cellular infiltration Matrix deposition Acquisition of mechanical properties	Maher *et al.*, 2010 Galley *et al.*, 2011
Sheep	Hyaluronic acid/polycaprolactone	No cells	6 weeks	Presence of synovium-like tissue Vessel formation Integration with the host tissue	Chiari *et al.*, 2006
Sheep	Hyaluronic acid/polycaprolactone	Chondrocytes	4 months	Fibrocartilaginous matrix deposition Foreign body reaction	Kon *et al.*, 2008
Sheep	Hyaluronic acid/polycaprolactone	Chondrocytes	12 months	Integration with the host tissue Connective tissue formation Vessel ingrowth Organized collagen network Cells with chondroid morphology Foreign body reaction	Kon *et al.*, 2012
Sheep	Polycarbonate–urethane	No cells	6 months	No extrusion No data on the biology of the implant	Zur *et al.*, 2011
Rabbit	Hyaluronan ester/gelatin	MSCs	6 and 12 weeks	Formation of meniscus-like tissue Organized collagen II distribution	Zellner *et al.*, 2010
Rabbit	Porcine small intestine submucosa	No cells	4, 12 and 24 weeks	Host cell infiltration	Gastel *et al.*, 2001
Rabbit	Polyglycolic acid (PGA)	Meniscal cells	10 and 36 weeks	Meniscus-like shape and histology Inferior collagen content and mechanical properties with respect to the native meniscus	Kang *et al.*, 2006
Rabbit	Polyvinyl alcohol–hydrogel (PVA–H)	No cells	24 months	Meniscus-like mechanical properties	Kobayashi *et al.*, 2005
Dog	Polyurethane	No cells	2 months	Fibrocartilaginous matrix deposition Collagen I and II deposition	Klompmaker *et al.*, 1996
Dog	Porcine small intestine submucosa	No cells	12 weeks	Meniscus-like tissue	Cook *et al.*, 1999
Dog	Estane polymer	No cells	6 months	Infiltration of fibro-vascular tissue Different compression modulus with respect to the native meniscus	Tienen *et al.*, 2006
Dog	Polycaprolactone–polyurethane (PCLPU)	No cells	6 and 24 months	Infiltration of fibrovascular tissue Collagen I deposition Collagen II and GAGs deposition in the inner portion No scaffold degradation after 24 months: no collagen organization	Welsing *et al.*, 2008
Goat	Porcine small intestine submucosa	No cells	12 weeks	Irregularly organized fibrous connective tissue Scarce tissue maturation	Bradley *et al.*, 2007

DOI: 10.1002/term

similar to those of normal control menisci 6 months after transplantation. In this animal model, a limitation of the meniscal allograft transplantation was described, consisting of shrinkage of the allografts resulting in a reduction of the tibial surface area covered by meniscal tissue, with a consequent doubling of the exposed articular cartilage (Canham and Stanish, 1986).

Similar data were also obtained in the *rabbit* model: the use of fresh menisci showed that both immediate and delayed meniscal allograft transplantation offer some initial protection to the cartilaginous surfaces of the knee (Cummins *et al*., 1997); however, delayed meniscal allograft transplantation leads to more graft shrinkage than immediate allograft transplantation (Rijk and Van Noorden 2002). Deep-frozen menisci have also been tested in the rabbit model and were found to be improved by association with a vascularized synovial flap: this approach promoted the invasion of repair tissue into the deeper matrix substance from the surface of the graft (Yamazaki and Tachibana 2003). No immune reaction or allograft rejection was described in these animal models, and this could be explained by the immune privilege of these grafts (Canham and Stanish, 1986).

Overall, although meniscal transplantation offers promising short- and middle-term results, the current research shows that degeneration of the articular cartilage still occurs and a better alternative needs to be developed. On the other hand, the use of different animal models seems to be appropriate in order to test preclinically the efficacy and safety of this approach.

8.2. Meniscus engineering

As an alternative to meniscal allograft transplantation, total or partial meniscal replacement can be achieved with the application of tissue-engineered composites, obtained through the combination of scaffolds with specific cell populations. Scaffolds for the tissue engineering of the meniscus may be categorized into four broad classes: synthetic polymers; hydrogels; ECM components; and tissue-derived materials. These scaffolds can be combined with different cell populations. Meniscal fibrochondrocytes represent the optimal cell source that can faithfully reproduce the native tissue; however, this approach presents several limitations; in particular, two surgical interventions would be required for a patient, a biopsy to obtain autologous meniscal cells, and a second procedure to implant the tissue-engineered meniscus. Moreover, tissue scarcity and current techniques yield only a limited number of meniscal cells and these cells dedifferentiate during monolayer expansion (Gunja and Athanasiou, 2007). For these reasons, other cell populations have been considered for meniscus engineering.

Stem cells can play an important role in rectifying meniscal damage, through their ability to differentiate and regenerate tissues and through their capability to produce cytokines and growth factors (Caplan and Dennis, 2006). Human embryonic stem cells (hESCs) have proved to be an emerging cell source for fibrocartilage tissue engineering (Hoben *et al*., 2008). Adult stem cells represent an alternative source to embryonic cells. Many studies have focused on the use of mesenchymal stem cells (MSCs). The large scientific interest surrounding these cells is due to two main abilities: first, MSCs have been observed to differentiate into many terminally differentiated cells which synthesize mesenchymal tissue (i.e. cartilage, bone, ligaments, muscle, fat, dermal and other connective tissue) and can therefore be used to engineer mesenchymal-derived tissue (Caplan, 2007); second, MSCs secrete a large variety of immuno-regulatory molecules, and contribute to the healing process of injured tissue by providing paracrine trophic mediators (Caplan and Dennis, 2006).

Different cell sources and different scaffolds have been combined and tested in several animal models for their ability to regenerate partial or total meniscal tissue. In some cases, cell-free scaffolds were used in order to promote the colonization of the host cells and drive their differentiation toward a fibrocartilaginous tissue; in a clinical setting, the use of an acellular scaffold would avoid the rescue of an autologous cell source and would reduce the surgery to only one step. Several studies in the literature describe the use of both large and small animals for the *in vivo* validation of cellular or acellular scaffolds (Pereira *et al*., 2011). Here, most of these studies are reported by emphasizing the animal models that were used, in order to highlight the results achieved for each model.

The *sheep* model has been widely used for partial and total regeneration of the meniscus (Table 2). In a model of partial meniscectomy, an acellular polyurethane scaffold (Actifit) was implanted, and after 6 months it was characterized by cellular infiltration and abundant matrix filling the scaffold and by local areas of integration with the host meniscus, which persisted through 12 months (Maher *et al*., 2010). This scaffold also showed a friction coefficient that decreased to near-native values after 6–12 months *in vivo*, suggesting the acquisition of native mechanical properties (Galley *et al*., 2011). Chiari *et al*. (2006) compared partial to total meniscus substitution by implanting an acellular absorbable material consisting of hyaluronic acid and polycaprolactone (PCL): the biomaterial showed excellent properties in terms of mechanical stability and tissue ingrowth; the implants maintained their shape and remained in position; they were also firmly bonded to the capsule, completely covered by a synovium-like tissue, and revealed signs of vessel formation. In cases of partial meniscus resection, collagen fibres had filled the gap between the biomaterial and original meniscus, indicating that a process of integration was occurring. However, the majority of the implants had been compressed, which caused graft extrusion to the periphery and into the posterior joint space, as well as irregularities and wrinkles on the implant surfaces. This effect was correlated with the use of an animal model: in fact, despite immobilization in the cast, full weight bearing could not be completely avoided. The same scaffold was also seeded with autologous chondrocytes and implanted for total meniscus substitution, in order to compare the contribution of seeded cells in the

DOI: 10.1002/term

regeneration of the tissue: the seeding of the scaffolds with autologous articular chondrocytes provided some benefit, with more fibrocartilaginous tissue also being produced at early stages of regeneration (4 months), demonstrating that the combination of this scaffold with a specific cell population can ameliorate scaffold maturation into a meniscal-like tissue. However, significant amounts of scaffold remain associated with a foreign body reaction at 4 months, suggesting that the use of this material may induce an inflammatory response in the host knee (Kon *et al*., 2008). This study was then prolonged to 12 months and all implants showed excellent integration with surrounding tissues, connective tissue formation and new vessels ingrowth. Compared with the 4 months results, the histological analysis revealed an improvement concerning the implant colonization, integration and cartilage metaplasia; in areas where the scaffold was resorbed, the regenerated tissue consisted of an avascular tissue, as expected in normal menisci; moreover, collagen appeared as a fine fibrillar network with orientation and cells showing a chondroid morphology in the cell-seeded group and a fibroblast aspect in the cell-free group; a foreign body response was still observed in the areas where the implant material was still present (Kon *et al*., 2012). Some other scaffolds were tested for the regeneration of the ovine meniscus: an acellular polycarbonate–urethane was implanted in the sheep knee and after 6 months and it showed no visible extrusion, migration or displacement from their original implantation site; however, no data regarding cell colonization were described for this material (Zur *et al*., 2011).

Some natural scaffolds were tested in the *rabbit* model. Zellner *et al*. (2010) developed a model for the total regeneration of the rabbit meniscus that consisted of a sponge made of a hyaluronan–ester (Fidia Advanced Biopolymers) and gelatin; this scaffold was combined with MSCs and different experimental approaches were compared for *in vivo* meniscal substitution. The cell-free matrices showed no improvement of meniscal healing: the bone marrow-loaded composite matrices revealed no improved healing of the created avascular meniscal defect compared to cell-free composite matrices; the repair tissue did not show fibrocartilaginous differentiation; the precultured stem cell–matrix composites did not significantly improve the repair over cell-free composite matrices; in particular, the integration of the repair tissue to the native meniscus was incomplete; the composites loaded with MSCs without *in vitro* preculture showed meniscal defect filling with the generation of meniscus-like repair tissue. In particular, meniscus-like distribution of type II collagen was observed in the repair tissue; the implantation of a composite loaded with platelet-rich plasma significantly failed to improve meniscal healing in the avascular zone compared to cell-free matrices and could not reach the results of MSC-loaded implants. This work demonstrates that MSCs can efficiently differentiate *in vivo* in response to the physiological biological and mechanical stimuli. In another model of partial meniscal defect, a natural material made of collagen, consisting of porcine small intestine submucosa, was implanted with the purpose of regenerating the lapine meniscal tissue: this preliminary approach led to the formation of a tissue characterized by host cells infiltration and with no evidence of rejection (Gastel *et al*., 2001); however, these encouraging data on the use of this natural material were not further developed in the rabbit model.

In the same animal model, total meniscus substitution was also performed. Kang *et al*. (2006) combined meniscal cells with a biodegradable scaffold having the rabbit meniscal shape and made of polyglycolic acid (PGA): after 10 weeks, the implants formed neo-menisci having a shape and histological structure similar to those of the native tissue; however, at 36 weeks, the collagen content and the mechanical properties differed from those of the native meniscus, demonstrating that cellular and acellular composites are often associated with low long-term stability and matrix maintenance. Another study of total meniscal regeneration focused on the use of an acellular meniscus made of polyvinyl alcohol–hydrogel (PVA-H): this model could prevent cartilage degeneration for a long time (2 years) and showed mechanical properties similar to those of native tissue (Kobayashi *et al*., 2005); however, no data are available on the scaffold colonization and matrix composition.

Some attempts in meniscus regeneration have been done also in the *dog* model. A longitudinal defect was created in the avascular zone of the canine meniscus and an acellular porous polyurethane material was implanted: after 2 months, fibrocartilaginous tissue developed inside the implants; both type I and II collagen could be detected in the newly formed fibrocartilage; moreover, the implant guided vascular tissue from the periphery towards the lesion, resulting in healing of the tear; after fibrocartilage had formed, vascularity decreased and was completely absent in mature fibrocartilage (Klompmaker *et al*., 1996). The use of porcine small intestinal submucosa was also applied for regeneration of the canine meniscus, in a model of partial meniscectomy: as observed in the rabbit model, this natural material was also able to induce an appropriate production of meniscal-like tissue in the dog, by providing a scaffold and a stimulus for cell and matrix regeneration (Cook *et al*., 1999). Total meniscus regeneration in the dog was first attempted by Tienen *et al*. (2006) with the use of an acellular biodegradable Estane polymer. At 6 months, this material showed infiltration of fibrovascular tissue into the implant but its compression modulus was found to be different from that of the native tissue; no data are available on the biochemical composition of the tissue. Then, Welsing *et al*. (2008), attempted lateral meniscus regeneration by replacing it with an acellular polycaprolactone-based polyurethane (PCLPU) material: after 6 months, a complete ingrowth of fibrovascular tissue was observed in the scaffold, with abundant collagen type I labelling; in the inner, higher-loaded region of the scaffold, remodelling into a cartilage-like tissue with type II collagen and GAGs was found. Moreover, tissue differentiation from fibrovascular to cartilage-like had progressed in the 24-month implants, particularly in the central region of

DOI: 10.1002/term

each scaffold; in the peripheral transitional zone to the synovial tissue, collagen type II staining was absent, similar to the distribution in the native meniscus; a homogeneous distribution of type I collagen was found throughout the scaffold. However, despite this differentiation toward cartilage-like tissue, the typical organization of meniscus tissue was not found in the scaffolds: one of the reasons for this lack of differentiation into typical meniscus tissue could be that the synthetic scaffold was not degraded after 24 months. These data suggest the importance of achieving not only regeneration of the meniscal tissue but also re-absorption of the scaffold material, in order to allow the newly formed matrix to recreate the physiological architecture of the tissue.

In the *goat* model, few experiments of meniscal regeneration have been done. In a model of subtotal meniscectomy, the porcine small intestine submucosa was implanted in order to regenerate the meniscal tissue but, this time, without encouraging results: after 12 weeks, the replacement tissue in the grafted menisci was characterized by the presence of dense, highly cellular, irregularly organized fibrous connective tissue; moreover, the replacement tissue was well vascularized and there was no well-defined hierarchical organization to the tissue; as a consequence of this scarce maturation into a meniscal-like tissue, no protection against cartilage degeneration was observed (Bradley *et al*., 2007).

9. Discussion

A wide variety of animal models have been used in meniscal studies, each presenting different advantages and disadvantages. The type of study usually limits the choices to few animal models.

The *dog* model is often used for meniscal studies, as it is characterized by easy handling, a variety of available sizes and increasing information on meniscal repair and replacement. As already reported by Chu *et al*. (2010), the canine model is characterized by an exposed stifle joint that makes the arthroscopic approach easier than with the other large animal models. However, the majority of surgical manipulations of menisci require arthrotomy, sometimes in conjunction with medial collateral ligament disruption, which alters joint kinematics and healing responses compared with arthroscopic surgery in humans (Arnoczky *et al*., 2010). Moreover, this model is considered expensive and this issue limits its use. The *rabbit* model is characterized by small size and, as a consequence, low expenses are required for purchasing and housing these animals; however, the functional range of motion and kinematics of the rabbit femorotibial joint are markedly different from those of the human knee: in particular, this animal is characterized by a high degree of knee flexion, with a consequent different loading condition compared with humans or other large animals; moreover, there are significant differences in the vascularity, collagen orientation and GAG content in rabbit menisci compared to human menisci (Chevrier *et al*., 2009) that may explain the different regenerative potential observed in the lapine model (Bendele, 2001). For all these reasons, the rabbit can not be considered the ideal model for studies of meniscus repair and regeneration with direct translation to humans.

Larger-sized animal models are characterized by higher expenses for their purchase and housing, but they more faithfully represent the human menisci, so they allow for the implantation of devices and implants that are closer in size to those designed for use in the human knee. The *sheep* model has been considered excellent by some authors for certain mechanical properties that closely match those of human tissue (Joshi *et al*., 1995); however, other authors have addressed the fact that the sheep uaually loads knees in flexion (Ghadially *et al*., 1986), while human knees are usually loaded during extension, so the distribution of compression and shearing forces of the ovine meniscus are different (Armstrong *et al*., 1995). Another limitation is represented by the fact that this animal model generally does not tolerate postoperative immobilization. Despite the different loading conditions that are quite common between the quadruped models and humans, the sheep has been widely used in meniscus engineering approaches, demonstrating that it is generally considered a reliable model for the *in vivo* validation of biomaterials and cells. In the *goat* model, the meniscus size and proportion are very similar to those of the human medial meniscus; also, the anatomy of the tibial insertion sites of the caprine lateral meniscus is comparable to the human model (Proffen *et al*., 2012). These data suggest that, from an anatomical point of view, the goat is the closest animal model to humans. Moreover, goats are less expensive than other large animal models and easy to handle (Chu *et al*., 2010). Despite the advantageous costs, the number of studies on meniscus replacement and repair in the goat is inferior to those done in the sheep, reflecting probably the reduced presence of facilities for goat housing and surgery. The *pig* model is also closely comparable to the human in terms of healing potential, anatomical structure, vascularization and weight; for these reasons, it represents an interesting model to test meniscal repair and replacement. Moreover, the miniature swine bred are able to maintain an adult weight and size comparable to adult men (Chu *et al*., 2010), making the pig an attractive model for tissue-engineering studies. However, despite the advantages of this model, it is not been widely used for meniscus regeneration studies, probably because of the high costs and reduced number of facilities that can host this large and potentially aggressive animal.

In general, the considered animals are quadruped models and their passive range of motion is different from the humans: Proffen *et al*. (2012) demonstrated that the *sheep*, *goat*, *pig*, *dog* and *rabbit* models have a physiological limit of extension with respect to humans, reflecting important differences in the mechanics and biology of meniscal tissue. As a matter of fact, the choice of the optimal animal model reflects a compromise between biological, technical and financial issues.

DOI: 10.1002/term

10. Conclusion

Taken together, all recent studies prompt the use of large animal models, which duplicate human meniscus anatomy and biomechanics more closely than small animals and may result in data that are more easily translatable to clinical practice. Large animals have been demonstrated to be good models for studying the safety and efficacy of innovative surgical procedures and materials, with or without cells, but still not optimal for testing the short-term efficacy of fragile biomaterials, because of the difficult management of postoperative weight bearing in these animals. Small animals are suitable models for preliminary studies, especially for their pricing, and have successfully been used for all the experimental approaches summarized in this review. They work well as a bridge from *in vitro* studies to large animal models, but their relevance for clinical practice is limited.

Considering the limits and advantages of the described animals, the *sheep* and *goat* models can be considered the ideal ones for meniscus studies, as they represent the best compromise between the required similarity to humans and the costs of their handling.

Acknowledgements

The authors thank Dr Rosa Ballis for drawing and composing Figure 1.

Conflict of interest

The authors have declared that there is no conflict of interest.

References

Abdel-Hamid M, Hussein MR, Ahmad AF. 2005; Enhancement of the repair of meniscal wounds in the red-white zone (middle third) by the injection of bone marrow cells in canine animal model. *Int J Exp Pathol* **86**(2): 117–123.

Adams ME, Muir H. 1981; The glycosaminoglycans of canine menisci. *Biochem J* **197** (2): 385–389.

Anderson K, Marx RG, Hannafin J, *et al*. 2000; Chondral injury following meniscal repair with a biodegradable implant. *J Arthrosc Rel Surg* **16**(7): 749–753.

Appleyard RC, Burkhardt D, Ghosh P, *et al*. 2003; Topographical analysis of the structural, biochemical and dynamic biomechanical properties of cartilage in an ovine model of osteoarthritis. *Osteoarthr Cartilage* **11**(1): 65–77.

Armstrong SJ, Read RA, Ghosh P, *et al*. 1993; Moderate exercise exacerbates the osteoarthritic lesions produced in cartilage by meniscectomy: a morphological study. *Osteoarthr Cartilage* **1**(2): 89–96.

Armstrong SJ, Read RA, Price R. 1995; Topographical variation within the articular cartilage and subchondral bone of the normal ovine knee joint: a histological approach. *Osteoarthr Cartilage* **3**(1): 25–33.

Arnoczky SP, Cook JL, Carter T, *et al*. 2010; Translational models for studying meniscal repair and replacement: what they can and cannot tell us. *Tissue Eng Part B Rev* **16**(1): 31–39.

Arnoczky SP, DiCarlo EF, O'Brien SJ, *et al*. 1992; Cellular repopulation of deep-frozen meniscal autografts: an experimental study in the dog. *J Arthrosc Rel Surg* **8**(4): 428–436.

Arnoczky SP, McDevitt CA, Schmidt MB, *et al*. 1988; The effect of cryopreservation on canine menisci: a biochemical, morphologic, and biomechanical evaluation. *J Orthop Res* **6**(1): 1–12.

Arnoczky SP, Warren RF. 1982; Microvasculature of the human meniscus. *Am J Sports Med* **10**(2): 90–95.

Arnoczky SP, Warren RF, McDevitt CA. 1990; Meniscal replacement using a cryopreserved allograft. An experimental study in the dog. *Clin Orthop Rel Res* **252**: 121–128.

Asik M, Sener N. 2002; Failure strength of repair devices versus meniscus suturing techniques. *Knee Surg Sports Traumatol Arthrosc* **10**(1): 25–29.

Assimakopoulos AP, Katonis PG, Agapitos MV, *et al*. 1992; The innervation of the human meniscus. *Clin Orthop Rel Res* **275**: 232–236.

Barber FA, Herbert MA. 2000; Meniscal repair devices. *J Arthrosc Rel Surg* **16**(6): 613–618.

Beaupre A, Choukroun R, Guidouin R, *et al*. 1986; Knee menisci. Correlation between microstructure and biomechanics. *Clin Orthop Rel Res* **208**: 72–75.

Bendele AM. 2001; Animal models of osteoarthritis. *J Musculoskel Neuron Interact* **1** (4): 363–376.

Berjon JJ, Munuera L, Calvo M. 1990; Meniscal repair following meniscectomy: mechanism and protective effect. Experimental study in the dog. *Skel Radiol* **19**(8): 567–574.

Berjon JJ, Munuera L, Calvo M. 1991; Degenerative lesions in the articular cartilage after meniscectomy: preliminary experimental study in dogs. *J Trauma* **31** (3): 342–350.

Beveridge JE, Shrive NG, Frank CB. 2011; Meniscectomy causes significant *in vivo* kinematic changes and mechanically induced focal chondral lesions in a sheep model. *J Orthop Res* **29**(9): 1397–1405.

Biedert RM, Stauffer E, Friederich NF. 1992; Occurrence of free nerve endings in the soft tissue of the knee joint. A histologic investigation. *Am J Sports Med* **20**(4): 430–433.

Bland YS, Ashhurst DE. 1996; Changes in the content of the fibrillar collagens and the expression of their mRNAs in the menisci of the rabbit knee joint during development and ageing. *Histochem J* **28**(4): 265–274.

Bradley MP, Fadale PD, Hulstyn MJ, *et al*. 2007; Porcine small intestine submucosa for repair of goat meniscal defects. *Orthopedics* **30**(8): 650–656.

Bray RC, Smith JA, Eng MK, *et al*. 2001; Vascular response of the meniscus to injury: effects of immobilization. *J Orthop Res* **19** (3): 384–390.

Brucker PU, Favre P, Puskas GJ, *et al*. 2010; Tensile and shear loading stability of all-inside meniscal repairs: an *in vitro* biomechanical evaluation. *Am J Sports Med* **38** (9): 1838–1844.

Bullough PG, Munuera L, Murphy J, *et al*. 1970; The strength of the menisci of the knee as it relates to their fine structure. *J Bone Joint Surg Br* **52**(3): 564–567.

Canham W, Stanish W. 1986; A study of the biological behavior of the meniscus as a transplant in the medial compartment of a dog's knee. *Am J Sports Med* **14**(5): 376–379.

Caplan AI. 2007; Adult mesenchymal stem cells for tissue engineering versus regenerative medicine. *J Cell Physiol* **213**(2): 341–347.

Caplan AI, Dennis JE. 2006; Mesenchymal stem cells as trophic mediators. *J Cell Biochem* **98**(5): 1076–1084.

Chang JH, Shen HC, Huang GS, *et al*. 2009; A biomechanical comparison of all-inside meniscus repair techniques. *J Surg Res* **155**(1): 82–88.

Chevrier A, Nelea M, Hurtig MB, *et al*. 2009; Meniscus structure in human, sheep, and rabbit for animal models of meniscus repair. *J Orthop Res* **27**(9): 1197–1203.

Chiari C, Koller U, Dorotka R, *et al*. 2006; A tissue engineering approach to meniscus regeneration in a sheep model. *Osteoarthr Cartilage* **14**(10): 1056–1065.

Chu CR, Szczodry M, Bruno S. 2010; Animal models for cartilage regeneration and repair. *Tissue Eng Part B Rev* **16**(1): 105–115.

Colombo C, Butler M, O'Byrne E, *et al*. 1983; A new model of osteoarthritis in rabbits. I. Development of knee joint pathology following lateral meniscectomy and section

of the fibular collateral and sesamoid ligaments. *Arthritis Rheum* **26**(7): 875–886.
Cook JL, Tomlinson JL, Kreeger JM, *et al*. 1999; Induction of meniscal regeneration in dogs using a novel biomaterial. *Am J Sports Med* **27**(5): 658–665.
Cummins JF, Mansour JN, Howe Z, *et al*. 1997; Meniscal transplantation and degenerative articular change: an experimental study in the rabbit. *J Arthrosc Rel Surg* **13** (4): 485–491.
Day B, Mackenzie WG, Shim SS, *et al*. 1985; The vascular and nerve supply of the human meniscus. *J Arthrosc Rel Surg* **1**(1): 58–62.
Elliott DM, Guilak F, Vail TP, *et al*. 1999; Tensile properties of articular cartilage are altered by meniscectomy in a canine model of osteoarthritis. *J Orthop Res* **17**(4): 503–508.
Esparza R, Gortazar AR, Forriol F. 2012; Cell study of the three areas of the meniscus: effect of growth factors in an experimental model in sheep. *J Orthop Res* **30**(10): 1647–51.
Eyre DR, Wu JJ. 1983; Collagen of fibrocartilage: a distinctive molecular phenotype in bovine meniscus. *FEBS Lett* **158** (2): 265–270.
Fabbriciani C, Lucania L, Milano G, *et al*. 1997; Meniscal allografts: cryopreservation vs deep-frozen technique. An experimental study in goats. *Knee Surg Sports Traumatol Arthrosc* **5**(2): 124–134.
Freeman MA, Wyke B. 1967; The innervation of the knee joint. An anatomical and histological study in the cat. *J Anat* **101**(3): 505–532.
Furumatsu T, Kanazawa T, Yokoyama Y, *et al*. 2011; Inner meniscus cells maintain higher chondrogenic phenotype compared with outer meniscus cells. *Connect Tissue Res* **52**(6): 459–465.
Galley NK, Gleghorn JP, Rodeo S, *et al*. 2011; Frictional properties of the meniscus improve after scaffold-augmented repair of partial meniscectomy: a pilot study. *Clin Orthop Rel Res* **469**(10): 2817–2823.
Gao J, Oqvist G, Messner K. 1994; The attachments of the rabbit medial meniscus. A morphological investigation using image analysis and immunohistochemistry. *J Anat* **185**(3): 663–667.
Gastel JA, Muirhead WR, Lifrak JT, *et al*. 2001; Meniscal tissue regeneration using a collagenous biomaterial derived from porcine small intestine submucosa. *J Arthrosc Rel Surg* **17**(2): 151–159.
Ghadially FN, Thomas I, Yong N, *et al*. 1978; Ultrastructure of rabbit semilunar cartilages. *J Anat* **125**(Pt 3): 499–517.
Ghadially FN, Wedge JH, Lalonde JM. 1986; Experimental methods of repairing injured menisci. *J Bone Joint Surg Br* **68**(1): 106–110.
Ghosh P, Taylor TK. 1987; The knee joint meniscus. A fibrocartilage of some distinction. *Clin Orthop Rel Res* **224**: 52–63.
Gunja NJ, Athanasiou KA. 2007; Passage and reversal effects on gene expression of bovine meniscal fibrochondrocytes. *Arthritis Res Ther* **9**(5): R93.
Hechtman KS, Uribe JW. 1999; Cystic hematoma formation following use of a biodegradable arrow for meniscal repair. *J Arthrosc Rel Surg* **15**(2): 207–210.
Hellio Le Graverand MP, Ou Y, Schield-Yee T, *et al*. 2001; The cells of the rabbit meniscus: their arrangement, interrelationship, morphological variations and cytoarchitecture. *J Anat* **198**(5): 525–535.
Herwig J, Egner E, Buddecke E. 1984; Chemical changes of human knee joint menisci in various stages of degeneration. *Ann Rheumat Dis* **43**(4): 635–640.
Hoben GM, Koay EJ, Athanasiou KA. 2008; Fibrochondrogenesis in two embryonic stem cell lines: effects of differentiation timelines. *Stem Cells* **26**(2): 422–430.
Horie M, Choi H, Lee RH, *et al*. 2012; Intra-articular injection of human mesenchymal stem cells (MSCs) promote rat meniscal regeneration by being activated to express Indian hedgehog that enhances expression of type II collagen. *Osteoarthr Cartilage* **20**(10): 1997–207.
Horie M, Sekiya I, Muneta T, *et al*. 2009; Intra-articular Injected synovial stem cells differentiate into meniscal cells directly and promote meniscal regeneration without mobilization to distant organs in rat massive meniscal defect. *Stem Cells* **27**(4): 878–887.
Hospodar SJ, Schmitz MR, Golish SR, *et al*. 2009; FasT-Fix versus inside-out suture meniscal repair in the goat model. *Am J Sports Med* **37**(2): 330–333.
Hotta H, Yamada H, Takaishi H, *et al*. 2005; Type II collagen synthesis in the articular cartilage of a rabbit model of osteoarthritis: expression of type II collagen C-propeptide and mRNA especially during early-stage osteoarthritis. *J Orthop Sci* **10**(6): 595–607.
Imler SM, Doshi AN, Levenston ME. 2004; Combined effects of growth factors and static mechanical compression on meniscus explant biosynthesis. *Osteoarthr Cartilage* **12**(9): 736–744.
Ingman AM, Ghosh P, Taylor TK. 1974; Variation of collagenous and non-collagenous proteins of human knee joint menisci with age and degeneration. *Gerontologia* **20**(4): 212–223.
Ionescu LC, Lee GC, Huang KL, *et al*. 2012; Growth factor supplementation improves native and engineered meniscus repair *in vitro*. *Acta Biomater* **8**(10): 3687–94.
Ishida K, Kuroda R, Miwa M, *et al*. 2007; The regenerative effects of platelet-rich plasma on meniscal cells *in vitro* and its *in vivo* application with biodegradable gelatin hydrogel. *Tissue Eng* **13**(5): 1103–1112.
Izal I, Acosta CA, Ripalda P, *et al*. 2008; *IGF-1* gene therapy to protect articular cartilage in a rat model of joint damage. *Arch Orthop Trauma Surg* **128**(2): 239–247.
Jackson DW, Simon T. 1993; Assessment of donor cell survival in fresh allografts (ligament, tendon, and meniscus) using DNA probe analysis in a goat model. *Iowa Orthop J* **13**: 107–114.
Joshi MD, Suh JK, Marui T, *et al*. 1995; Interspecies variation of compressive biomechanical properties of the meniscus. *J Biomed Mater Res* **29**(7): 823–828.
Kambic HE, McDevitt CA. 2005; Spatial organization of types I and II collagen in the canine meniscus. *J Orthop Res* **23**(1): 142–149.
Kang SW, Son SM, Lee JS, *et al*. 2006; Regeneration of whole meniscus using meniscal cells and polymer scaffolds in a rabbit total meniscectomy model. *J Biomed Mater Res A* **77**(4): 659–671.
Kelly BT, Potter HG, Deng XH, *et al*. 2006; Meniscal allograft transplantation in the sheep knee: evaluation of chondroprotective effects. *Am J Sports Med* **34**(9): 1464–1477.
Kennedy JC, Alexander IJ, Hayes KC. 1982; Nerve supply of the human knee and its functional importance. *Am J Sports Med* **10**(6): 329–335.
Klompmaker J, Veth RP, Jansen HW, *et al*. 1996; Meniscal replacement using a porous polymer prosthesis: a preliminary study in the dog. *Biomaterials* **17**(12): 1169–1175.
Kobayashi M, Chang YS, Oka M. 2005; A two year *in vivo* study of polyvinyl alcohol-hydrogel (PVA-H) artificial meniscus. *Biomaterials* **26**(16): 3243–3248.
Kon E, Chiari C, Marcacci M, *et al*. 2008; Tissue engineering for total meniscal substitution: animal study in sheep model. *Tissue Eng Part A* **14**(6): 1067–1080.
Kohn D, Moreno B. 1995; Meniscus insertion anatomy as a basis for meniscus replacement: a morphological cadaveric study. *Arthroscopy* **11**(1): 96–103.
Kon E, Filardo G, Tschon M, *et al*. 2012; Tissue engineering for total meniscal substitution: animal study in sheep model – results at 12 months. *Tissue Eng Part A* **18** (15–16): 1573–82.
Kopf S, Birkenfeld F, Becker R, *et al*. 2010; Local treatment of meniscal lesions with vascular endothelial growth factor. *J Bone Joint Surg Am* **92**(16): 2682–2691.
LeRoux MA, Arokoski J, Vail TP, *et al*. 2000; Simultaneous changes in the mechanical properties, quantitative collagen organization, and proteoglycan concentration of articular cartilage following canine meniscectomy. *J Orthop Res* **18**(3): 383–392.
Little C, Smith S, Ghosh P, *et al*. 1997; Histomorphological and immunohistochemical evaluation of joint changes in a model of osteoarthritis induced by lateral meniscectomy in sheep. *J Rheumatol* **24** (11): 2199–2209.
Maher SA, Rodeo SA, Doty SB, *et al*. 2010; Evaluation of a porous polyurethane scaffold in a partial meniscal defect ovine model. *J Arthrosc Rel Surg* **26**(11): 1510–1519.
McDevitt CA, Webber RJ. 1990; The ultrastructure and biochemistry of meniscal cartilage. *Clin Orthop Rel Res* **252**: 8–18.
McNickle AG, Wang VM, Shewman EF, *et al*. 2009; Performance of a sterile meniscal allograft in an ovine model. *Clin Orthop Rel Res* **467**(7): 1868–1876.
Meller R, Schiborra F, Brandes G, *et al*. 2009; Postnatal maturation of tendon, cruciate ligament, meniscus and articular cartilage: a histological study in sheep. *Ann Anat* **191**(6): 575–585.
Menche DS, Phillips GI, Pitman MI, *et al*. 1999; Inflammatory foreign-body reaction to an arthroscopic bioabsorbable meniscal arrow repair. *J Arthrosc Rel Surg* **15**(7): 770–772.
Merkel KH. 1980; The surface of human menisci and its aging alterations during age. A combined scanning and transmission electron microscopic examination (SEM, TEM). *Arch Orthop Traum Surg* **97**(3): 185–191.
Messner K, Fahlgren A, Ross I, *et al*. 2000; Simultaneous changes in bone mineral density and articular cartilage in a rabbit meniscectomy model of knee osteoarthrosis. *Osteoarthr Cartilage* **8**(3): 197–206.
Mikic ZD, Brankov MZ, Tubic MV, *et al*. 1993; Allograft meniscus transplantation in the dog. *Acta Orthop Scand* **64**(3): 329–332.
Miller MD, Kline AJ, Jepsen KG. 2004; All-inside meniscal repair devices: an experimental study in the goat model. *Am J Sports Med* **32**(4): 858–862.

DOI: 10.1002/term

Miller MD, Ritchie JR, Gomez BA, *et al*. 1995; Meniscal repair. An experimental study in the goat. *Am J Sports Med* **23**(1): 124–128.
Moon MS, Kim JM, Ok IY. 1984; The normal and regenerated meniscus in rabbits. Morphologic and histologic studies. *Clin Orthop Relat Res* **182**: 264–269.
Mora G, Alvarez E, Ripalda P, *et al*. 2003; Articular cartilage degeneration after frozen meniscus and Achilles tendon allograft transplantation: experimental study in sheep. *J Arthrosc Rel Surg* **19**(8): 833–841.
Moskowitz RW, Davis W, Sammarco J, *et al*. 1973; Experimentally induced degenerative joint lesions following partial meniscectomy in the rabbit. *Arthritis Rheum* **16** (3):397–405.
Morgan CD, Wojtys EM, Casscells CD, *et al*. 1991; Arthroscopic meniscal repair evaluated by second-look arthroscopy. *Am J Sports Med* **19**(6): 632–637; discussion, 637–638.
Murphy JM, Fink DJ, Hunziker EB, *et al*. 2003; Stem cell therapy in a caprine model of osteoarthritis. *Arthritis Rheumat* **48**(12): 3464–3474.
Narita A, Takahara M, Sato D, *et al*. 2012; Biodegradable gelatin hydrogels incorporating fibroblast growth factor 2 promote healing of horizontal tears in rabbit meniscus. *J Arthrosc Rel Surg* **28** (2): 255–263.
Newman AP, Anderson DR, Daniels AU, *et al*. 1989; The effect of medial meniscectomy and coronal plane angulation on *in vitro* load transmission in the canine stifle joint. *J Orthop Res* **7**(2): 281–291.
O'Connor BL. 1984; The mechanoreceptor innervation of the posterior attachments of the lateral meniscus of the dog knee joint. *J Anat* **138**(1): 15–26.
O'Connor BL, McConnaughey JS. 1978; The structure and innervation of cat knee menisci, and their relation to a sensory hypothesis of meniscal function. *Am J Anat* **153**(3): 431–442.
Oakley SP, Lassere MN, Portek I, *et al*. 2004; Biomechanical, histologic and macroscopic assessment of articular cartilage in a sheep model of osteoarthritis. *Osteoarthr Cartilage* **12**(8): 667–679.
Oliverson TJ, Lintner DM. 2000; Biofix arrow appearing as a subcutaneous foreign body. *J Arthrosc Rel Surg* **16**(6): 652–655.
Otte S, Klinger HM, Beyer J, *et al*. 2002; Complications after meniscal repair with bioabsorbable arrows: two cases and analysis of literature. *Knee Surg Sports Traumatol Arthrosc* **10**(4): 250–253.
Pereira H, Frias AM, Oliveira JM, *et al*. 2011; Tissue engineering and regenerative medicine strategies in meniscus lesions. *J Arthrosc Rel Surg* **27**(12): 1706–1719.
Peretti GM, Gill TJ, Xu JW, *et al*. 2004; Cell-based therapy for meniscal repair: a large animal study. *Am J Sports Med* **32**(1): 146–158.
Petersen W, Tillmann B. 1995; Age-related blood and lymph supply of the knee menisci. A cadaver study. *Acta Orthop Scand* **66**(4): 308–312.
Petersen W, Tillmann B. 1998; Collagenous fibril texture of the human knee joint menisci. *Anat Embryol* **197**(4): 317–324.
Proctor CS, Schmidt MB, Whipple RR, *et al*. 1989; Material properties of the normal medial bovine meniscus. *J Orthop Res* **7**(6): 771–782.
Proffen BL, McElfresh M, Fleming BC, *et al*. 2012; A comparative anatomical study of the human knee and six animal species. *Knee* **19**(4): 493–499.
Rankin CC, Lintner DM, Noble PC, *et al*. 2002; A biomechanical analysis of meniscal repair techniques. *Am J Sports Med* **30**(4): 492–497.
Rijk PC, Van Noorden CJ. 2002; Structural analysis of meniscal allografts after immediate and delayed transplantation in rabbits. *J Arthrosc Rel Surg* **18**(9): 995–1001.
Ritchie JR, Miller MD, Bents RT, *et al*. 1998; Meniscal repair in the goat model. The use of healing adjuncts on central tears and the role of magnetic resonance arthrography in repair evaluation. *Am J Sports Med* **26**(2): 278–284.
Rosso C, Kovtun K, Dow W, *et al*. 2011; Comparison of all-inside meniscal repair devices with matched inside-out suture repair. *Am J Sports Med* **39**(12): 2634–2639.
Salata MJ, Gibbs AE, Sekiya JK. 2010; A systematic review of clinical outcomes in patients undergoing meniscectomy. *Am J Sports Med* **38**(9): 1907–1916.
Scotti C, Pozzi A, Mangiavini L, *et al*. 2009; Healing of meniscal tissue by cellular fibrin glue: an *in vivo* study. *Knee Surg Sports Traumatol Arthrosc* **17**(6): 645–651.
Segawa Y, Muneta T, Makino H, *et al*. 2009; Mesenchymal stem cells derived from synovium, meniscus, anterior cruciate ligament, and articular chondrocytes share similar gene expression profiles. *J Orthop Res* **27**(4): 435–441.
Seo JH, Li G, Shetty GM, *et al*. 2009; Effect of repair of radial tears at the root of the posterior horn of the medial meniscus with the pullout suture technique: a biomechanical study using porcine knees. *J Arthrosc Rel Surg* **25**(11): 1281–1287.
Somer L, Somer T. 1983; Is the meniscus of the knee joint a fibrocartilage? *Acta Anat Basel* **116** (3):234–244.
Son M, Levenston ME. 2012; Discrimination of meniscal cell phenotypes using gene expression profiles. *Eur Cells Mater* **23**: 195–208.
Song EK, Lee KB, Yoon TR. 2001; Aseptic synovitis after meniscal repair using the biodegradable meniscus arrow. *J Arthrosc Rel Surg* **17**(1): 77–80.
Sonoda M, Harwood FL, Amiel ME, *et al*. 2000; The effects of hyaluronan on tissue healing after meniscus injury and repair in a rabbit model. *Am J Sports Med* **28** (1): 90–97.
Stone KR, Rodkey WG, McKinney LA, *et al*. 1995; Autogenous replacement of the meniscus cartilage: analysis of results and mechanisms of failure. *J Arthrosc Rel Surg* **11**(4): 395–400.
Sweigart MA, Zhu CF, Burt DM, *et al*. 2004; Intraspecies and interspecies comparison of the compressive properties of the medial meniscus. *Ann Biomed Eng* **32**(11): 1569–1579.
Tengrootenhuysen M, Meermans G, Pittoors K, *et al*. 2011; Long-term outcome after meniscal repair. *Knee Surg Sports Traumatol Arthrosc* **19**(2): 236–241.
Tienen TG, Heijkants RG, de Groot JH, *et al*. 2006; Replacement of the knee meniscus by a porous polymer implant: a study in dogs. *Am J Sports Med* **34**(1): 64–71.
Verbruggen G, Verdonk R, Veys EM, *et al*. 1996; Human meniscal proteoglycan metabolism in long-term tissue culture. *Knee Surg Sports Traumatol Arthrosc* **4**(1): 57–63.
Verdonk PC, Forsyth RG, Wang J, *et al*. 2005; Characterisation of human knee meniscus cell phenotype. *Osteoarthr Cartilage* **13** (7): 548–560.
Warren RF. 1985; Arthroscopic meniscus repair. *J Arthrosc Rel Surg* **1**(3): 170–172.
Weinand C, Peretti GM, Adams SB, *et al*. 2006; An allogenic cell-based implant for meniscal lesions. *Am J Sports Med* **34**(11): 1779–1789.
Welsing RT, van Tienen TG, Ramrattan N, *et al*. 2008; Effect on tissue differentiation and articular cartilage degradation of a polymer meniscus implant: a 2-year follow-up study in dogs. *Am J Sports Med* **36**(10): 1978–1989.
Wilson AS, Legg PG, McNeur JC. 1969; Studies on the innervation of the medial meniscus in the human knee joint. *Anat Rec* **165** (4): 485–491.
Wyland DJ, Guilak F, Elliott DM, *et al*. 2002; Chondropathy after meniscal tear or partial meniscectomy in a canine model. *J Orthop Res* **20**(5): 996–1002.
Yamazaki K, Tachibana Y. 2003; Vascularized synovial flap promoting regeneration of the cryopreserved meniscal allograft: experimental study in rabbits. *J Orthop Sci* **8**(1): 62–68.
Young AA, McLennan S, Smith MM, *et al*. 2006; Proteoglycan 4 downregulation in a sheep meniscectomy model of early osteoarthritis. *Arthritis Res Ther* **8**(2): R41.
Zantop T, Eggers AK, Musahl V, *et al*. 2005; Cyclic testing of flexible all-inside meniscus suture anchors: biomechanical analysis. *Am J Sports Med* **33**(3): 388–394.
Zellner J, Mueller M, Berner A, *et al*. 2010; Role of mesenchymal stem cells in tissue engineering of meniscus. *J Biomed Mater Res A* **94**(4): 1150–1161.
Zimny ML, Albright DJ, Dabezies E. 1988; Mechanoreceptors in the human medial meniscus. *Acta Anat* **133**(1): 35–40.
Zur G, Linder-Ganz E, Elsner JJ, *et al*. 2011; Chondroprotective effects of a polycarbonate–urethane meniscal implant: histopathological results in a sheep model. *Knee Surg Sports Traumatol Arthrosc* **19**(2): 255–263.

DOI: 10.1002/term