

VIDEOS IN CLINICAL MEDICINE

Bone Marrow Aspiration and Biopsy

Suman Malempati, M.D., Sarita Joshi, M.D., Susanna Lai, M.P.H.,
Dana A.V. Braner, M.D., and Ken Tegtmeier, M.D.

From the Division of Hematology and Oncology (S.M.) and the Division of Critical Care Medicine (S.L., D.A.V.B.), Department of Pediatrics, Doernbecher Children's Hospital, Oregon Health and Science University, Portland; and the Division of Hematology and Oncology (S.J.) and the Division of Critical Care Medicine (K.T.), Cincinnati Children's Hospital Medical Center, Cincinnati.

N Engl J Med 2009;361:e28.

Copyright © 2009 Massachusetts Medical Society.

INDICATIONS

Bone marrow aspiration is performed to obtain specimens used to assess cellular morphology and to conduct specialized tests on the bone marrow, such as flow cytometry for immunophenotypic analysis, cytogenetic studies, or molecular studies. It is a time-tested, reproducible procedure used for the evaluation of hematologic conditions, cancers, metastatic disease, and storage disorders as well as some chronic systemic conditions. Bone marrow biopsy is often performed as part of the aspiration procedure and can provide more specific information about the cellularity of the marrow and the extent of disease.¹ As with any invasive procedure, bone marrow aspiration and biopsy are best performed by trained clinicians who are aware of the indications and contraindications and knowledgeable about the management of potential complications.

CONTRAINDICATIONS

Bone marrow aspiration and biopsy have no absolute contraindications, but there may be relative contraindications related to the general condition of the patient or the risk of anesthesia or deep sedation. An active infection at the proposed site of aspiration, such as the posterior iliac crest, would preclude the use of the site. However, the procedure can be performed at an alternative site if the indication for the procedure warrants it. Other sites that have been used successfully to perform aspirations include the anterior iliac crest, the manubrium of the sternum, the tibia (in infants), and, in extremely rare instances, the vertebral body. Thrombocytopenia and other coagulopathies are not contraindications for the procedure if it is executed by a skilled clinician. The sternum is not recommended as a site for biopsy.

EQUIPMENT

To perform the procedure you will need sterile solution (preferably chlorhexidine, unless it is contraindicated, in which case povidone-iodine may be used), sterile drapes, sterile gloves, local anesthesia (1% plain lidocaine or 0.25% or 0.5% bupivacaine), a 25-gauge needle with two 5-ml syringes for administration of local anesthetic, an 11-blade scalpel for stab incision, two larger syringes (10 ml or 35 ml), a bone marrow aspiration needle (preferably disposable), a bone marrow biopsy needle (Jamshidi, Islam, or disposable snare-coil biopsy needle), slides, preservative-free heparin sulfate, and, if a trephine-biopsy specimen is to be obtained, formalin or another fixative. Local anesthetic can be buffered with sterile sodium bicarbonate to minimize irritation from the injection.

SEDATION

Bone marrow aspiration and biopsy are painful procedures. At a minimum, the patient should receive a judicious amount of local anesthetic. For pediatric patients, the administration of deep sedation by an anesthesiologist or other qualified pro-

vider of sedation has become the standard of care — it should also be considered for patients of any age who may be anxious about pain during the procedure.

PROCEDURE

Obtain consent from the patient or from a parent or guardian. Review patient identifiers to make sure you will perform the procedure on the intended patient. Be sure that the site you plan to use is the correct one. If the posterior iliac crest is the chosen site, patients are generally placed in the lateral decubitus position or the prone position; the video demonstrates aspiration and biopsy with the patient in the decubitus position. Sterilize the site with the sterile solution, place a sterile drape over the site, and administer local anesthesia, letting it infiltrate the skin, soft tissues, and periosteum.

BONE MARROW ASPIRATION

After local anesthesia has taken effect, make an incision through which you can introduce the bone marrow aspiration needle. Some needles used for intraosseous access have a guard in place to keep the needle from passing all the way through the bone. If a guard is present, you should remove it before starting bone marrow aspiration, to ensure adequate depth of penetration. Since the ilium is a large bone, the marrow space should be easy to locate, but the angle of entry is also important. In general, the needle should be advanced at an angle completely perpendicular to the bony prominence of the iliac crest (Fig. 1). Once the needle passes through the cortex and enters the marrow cavity, it should stay in place without being held.

Once the periosteum has been penetrated, use pressure to advance the needle through the cortex and rotate the needle in a semicircular motion, alternating clockwise and counterclockwise movements. If the patient is in the lateral position, you may stabilize the hip with your other hand so that you can get a better feel for the position and depth of the needle. You may use the thumb of this hand to mark the desired site and to prevent accidental repositioning of the needle. You will feel a slight give, after which you will feel that the needle is fixed solidly within the bone. Remove the stylet and aspirate approximately 1 ml of unadulterated bone marrow into a syringe (Fig. 2). An assistant should take the specimen from you and assess it for the presence of bony spicules; sometimes this can be done by merely looking at the flow of the blood in the syringe, but it is more easily achieved by spreading a drop of blood on a slide or dish and allowing it to spread. Bony spicules will appear as irregularities in the otherwise smooth surface of the drop (Fig. 3). If the specimen shows spicules, the assistant should use it to make smear slides immediately. If spicules are sparse or are not present, a new sample should be obtained from a slightly different site.

At this point, speed is important. Leave the needle in place and fill sequential syringes that have been prepared with heparin or other anticoagulants or preservatives, depending on the requirements for specific studies to withdraw samples for additional analysis. Then remove the needle, either after reinserting the stylet or with the syringe attached.

BONE MARROW BIOPSY

You may use the same skin incision to perform a subsequent core biopsy, but adjust the needle for insertion at a different angle into the bone itself. With a clockwise motion, introduce the needle with the stylet in place to puncture the periosteum. Then withdraw the stylet and advance the needle with a semicircular or circular motion to a depth of approximately 2 cm. You may use the stylet to assess the depth of the specimen by gently inserting it into the needle until resistance is met. The

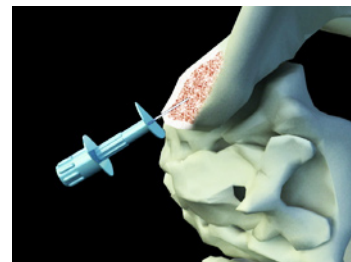


Figure 1. Bone marrow aspiration needle inserted into the iliac crest at an angle perpendicular to the bony prominence.

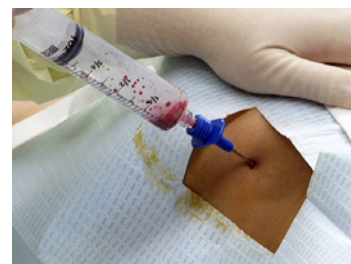

Figure 2. Aspiration of bone marrow into a syringe.

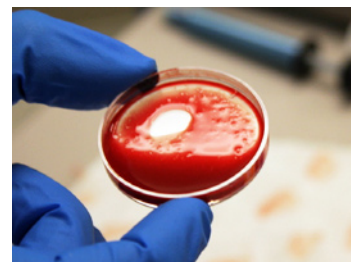


Figure 3. Bony spicules in the aspirate confirm the presence of bone marrow.

REFERENCES

1. Bain BJ. Bone marrow trephine biopsy. *J Clin Pathol* 2001;54:737-42.
2. *Idem*. Bone marrow biopsy morbidity and mortality. *Br J Haematol* 2003;121:949-51.
3. *Idem*. Morbidity associated with bone marrow aspiration and trephine biopsy — a review of UK data for 2004. *Haematologica* 2006;91:1293-4.
4. Arellano-Rodrigo E, Real MI, Muntañola A, et al. Successful treatment by selective arterial embolization of severe retroperitoneal hemorrhage secondary to bone marrow biopsy in post-polycythemic myelofibrosis. *Ann Hematol* 2004;83:67-70.
5. Wahid SF, Md-Anshar F, Mukari SA, Rahmat R. Massive retroperitoneal hematoma with secondary hemothorax complicating bone marrow trephine biopsy in polycythemia vera. *Am J Hematol* 2007;82:943-4.

Copyright © 2009 Massachusetts Medical Society.

distance from the hub of the needle to the screw-top of the stylet approximates the length of the biopsy specimen within the needle. In an adult, an adequate specimen is approximately 2 cm long. To make sure the biopsy specimen is not left behind when you remove the needle, twist the needle clockwise and counterclockwise several times and rock it gently back and forth in multiple directions, then slowly extract it from the bone. Once the needle is removed, extract the core by using another, thinner sterile stylet or a probe to push the specimen from the needle tip out the proximal end of the needle onto a sterile gauze or slide. The biopsy specimen can be used to make touch-preparation slides at the bedside, but it should then be placed in a labeled sterile container.

Apply pressure to obtain adequate hemostasis (this may take a few minutes, or longer in a patient with coagulopathy), then clean the area with alcohol or another disinfectant. Place clean or antibiotic-soaked gauze at the incision site, using a compression bandage. The bandage may be removed after 24 hours; once the bandage is removed, the area should be monitored for infection or delayed bleeding.

COMPLICATIONS

A bone marrow aspiration is a potentially hazardous procedure. Complications have been documented but are rare (incidence, 0.12 to 0.30%).² All trainees must be supervised until competence is ensured. Those trained to carry out this procedure may include not only medical practitioners but also midlevel care providers.

Complications may include trauma to neighboring structures (e.g., lacerations of a branch of the gluteal artery) and soft tissues, infection, and hemorrhage. The most commonly reported complication is hemorrhage.³ Risk factors for hemorrhage include thrombocytopenia, concurrent use of anticoagulants, and the presence of an underlying myeloproliferative disorder. Retroperitoneal hematomas resulting from trephine biopsies^{4,5} have been reported, as have (on rare occasions) fractures of the underlying bone, especially in patients with osteoporosis. Patients and their family members should be instructed to watch for signs of bleeding or swelling at the procedure site and to seek immediate attention for anything out of the ordinary, particularly light-headedness or altered mental status that could represent early signs of shock.

No potential conflict of interest relevant to this article was reported.